

**PATIENT PRESENTING CLINICAL SIGNS**

Maui Carneras

History: Inconsistent appetite, PU/PD, inappropriate urination, possible incontinence, elevated liver values

**SPECIES**

Canine

**ECHOCARDIOGRAPHIC FINDINGS**

2D, M-mode, and Doppler study.

**BREED**

Lab Mix

Left atrial size is normal. The mitral valve is normal. Left ventricular dimensions are normal. Left ventricular systolic function is hyperdynamic. The aorta and aortic valve appear normal, though there is mildly increased flow velocity in the ascending aorta. Right atrial and right ventricular dimensions are normal. The tricuspid valve is normal. The pulmonary artery and pulmonic valve are normal. No shunting lesions are visualized. No pericardial effusion or cardiac masses are seen.

**SEX**

FS

LA - 34.9 mm  
LVIDd - 36.2 mm  
LVIDs - 19.0 mm  
FS - 47.5%  
LVOT - 2.04 m/s  
RVOT - 1.17 m/s

**AGE**

11 years

**WEIGHT**

62#

**ASSESSMENT/RECOMMENDATIONS**

Normal echocardiogram

**INTERPRETED BY**

Keith Blass, DVM,  
MS, DACVIM

This examination demonstrates no evidence of structural heart disease. Maui does have mildly increased flow velocity in her aorta, therefore, it's possible that she could develop a left basilar functional/innocent murmur.

No therapy is recommended based on this exam.

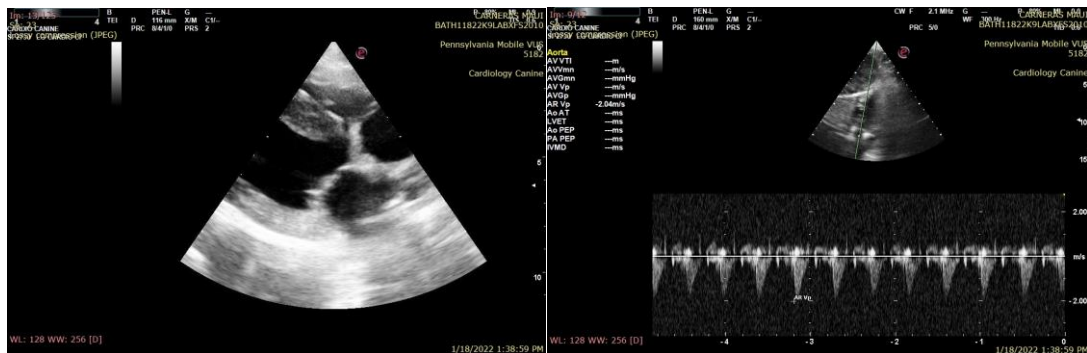**IMAGING PERFORMED BY**

Rebekah Jakum, CVT  
ARDMS/RVT

A recheck echocardiogram is recommended if new physical exam and/or clinical abnormalities suggestive of cardiac dysfunction develop.

**HOSPITAL NAME**

Lehigh Valley AH  
(Bath)



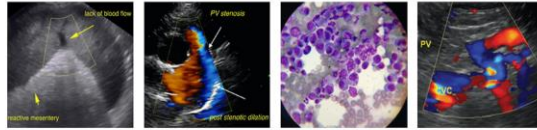
**REFERRING VET**

Dr. Tan

**DATE**

1.18.2022

The information and recommendations provided are based on the images presented by the referring veterinarian. No evaluation can be communicated regarding pathology that was not visible in the image/video clips provided.



**PATIENT**

Thank you for this referral. If the clinical or image interpretation does not parallel your findings or if I can be of any further assistance please contact me.

Maui Carneras

**SPECIES**

Keith Blass, DVM, MS, DACVIM (Cardiology)

KeithBlass@gmail.com

Canine

631-804-5754

**BREED**

Lab Mix

**SEX**

FS

**AGE**

11 years

**WEIGHT**

62#

**INTERPRETED BY**

Keith Blass, DVM,  
MS, DACVIM

**IMAGING  
PERFORMED BY**

Rebekah Jakum, CVT  
ARDMS/RVT

**HOSPITAL NAME**

Lehigh Valley AH  
(Bath)

**REFERRING VET**

Dr. Tan

**DATE**

1.18.2022